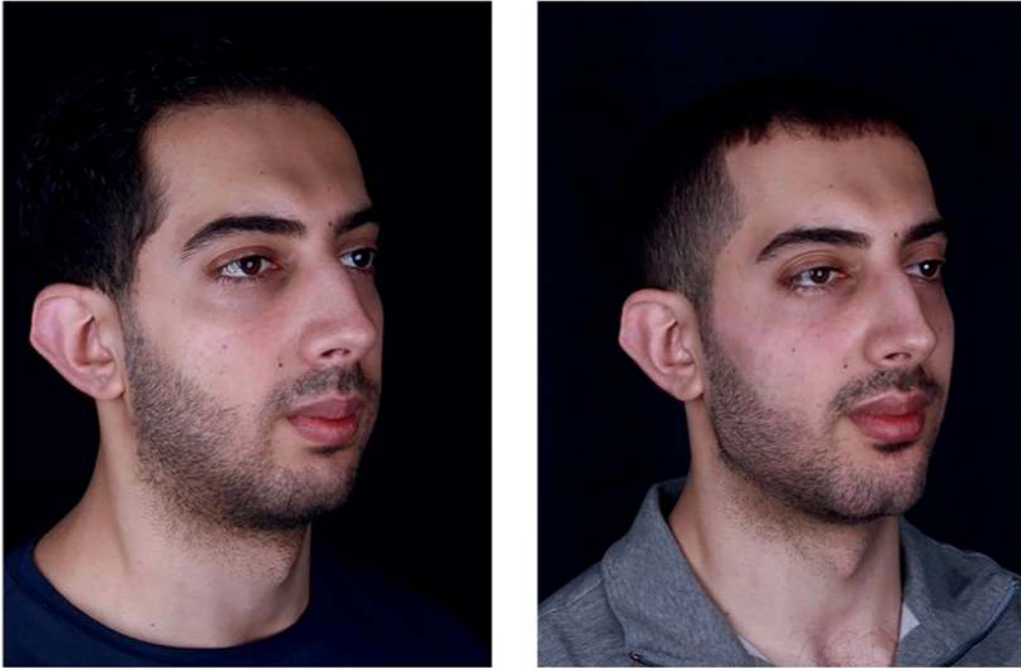



Left: before, Right: after

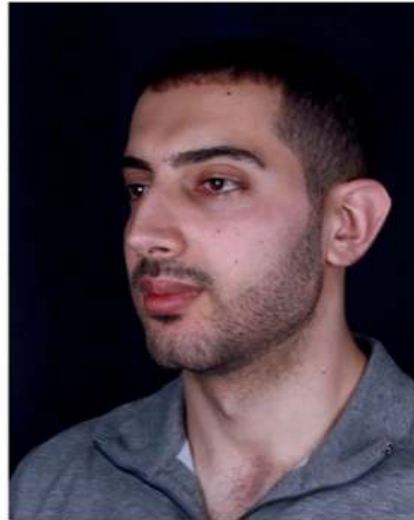
Defining feature

Dr MJ Rowland-Warmann presents a male jawline treatment using collagen-stimulating filler



DR MJ ROWLAND-WARMANN

Dr MJ Rowland-Warmann (BDS BSc MSc Aes.Med. MClintDent Orthod. PGDip Endod. PGCert.MedEd. M.J.D.F) is the founder and lead clinician at Smileworks dental and aesthetics clinic in Liverpool. She has a special interest in skincare, dermal filler, toxin and thread-lift treatment and the management of dermal filler complications. Follow her on Instagram: [@dr_mj_smileworks](#)



Left: before, Right: after

I have seen an exponential increase in demand for jawline definition in male patients of late. The ultimate objective when creating a more defined jawline is finding a product which is firm enough to provide lift, but which achieves natural-looking results without adding too much volume to the face.

CONSULTATION

In this particular case, the patient, a male, wanted a more defined jawline. He felt his jaw was “too far back” and his nose out of proportion with the rest of his features. He wanted to “masculinise” his face – a request which is becoming more and more common. The patient had carried out a lot of research, was very realistic about his expectations from the treatment and was aware he did not want to be treated by a non-medic.

The first step when treating a patient is to take pictures at all angles and expressions – front, three quarters and profile. These are put onto the screen to allow co-diagnosis to be used to provide treatment options. This allows for identification of the problems and treatment planning based on objective science rather than subjective opinion. Considering frontal views, symmetry assessment revealed his right cheek was slightly flatter than the left. Turning the focus to the profile view, this revealed the patient had a class-II skeletal profile with a retruded

mandible. The lower facial third lacked anterior and inferior projection and required augmentation. This was further illustrated by annotating the true vertical line to assess the position of the chin – the retruded mandible can make the lower face look smaller and less defined.

The FMPA (Frankfort mandibular planes angle) revealed the patient is a high angle (FMPA is more than 28 degrees and bisects in front of the back of the head). With a high FMPA and a retruded chin, this patient is an ideal candidate for jawline filler to contour the jaw and advance the chin, while also adding vertical height to the chin. The nasolabial angle is slightly open, but his lips are already large and so jawline contouring using dermal filler was planned with a view to assessing the resultant NL angle once this was completed. The projection and shape of the nose was discussed. However, due to the diminutive chin, augmenting the lower face may result in better profile harmony of the nose.

Mandibular advancement surgery, not having treatment, and treatment with fillers were all discussed and considered as options, and the patient wanted to have treatment with the latter. On discussion of the merits of HA filler versus Ellansé collagen-stimulating filler from Sinclair Pharma, the patient was keen to have treatment with Ellansé due to longevity and collagenesis.

Ellansé is comprised of a patented composition – 70% carboxymethyl

cellulose (CMC)-based gel carrier and 30% polycaprolactone (PCL) microspheres. The length of the polymer chain of the PCL is what gives Ellansé its longevity, lasting from 18 months up to 24 months. The collagen stimulation is brought about by bio-absorbable medical polymer PCL. When microspheres made from this polymer, suspended in the filler gel, are absorbed by the body, this triggers a reaction which results in the body generating its own repair collagen.

TREATMENT PLAN

Due to the significant need for volume in the chin, a two-stage approach was considered as optimal. This was staggered over two sessions, with a four-month break in between treatments. This would allow the patient to gain collagen production and mild contour after the first appointment and then top up in a further session if needed.

Phase one

During the first of the two treatments sessions, 6ml of Ellansé M was used. The treatment protocol was as follows:

- Bolus injections periosteally to the angle of the mandible to widen jaw.
 - Ellansé placed to the deep medial cheek fat to gain support to the mid face via lateral access at the zygomatic arch using a cannula (periosteally).
 - Placement of Ellansé sub-dermally from the angle of the mandible vertically to aid posterior contour, again using a cannula.
 - Placement of Ellansé sub-dermally from the midpoint of the lower border of the mandible, taking care to avoid the facial artery and avoiding any placement that would add weight to the jowl area.
- Placement to the posterior jawline with a cannula.
- Placement to the anterior jawline and chin in a multi-layer technique using a cannula:
 - Deep to the mentalis muscle to broaden the chin
 - Superficial to add anterior and inferior projection
 - Placement sub-dermally to the chin crease to assist in labial support and remove the labio-mental crease and assist in rotating the chin clockwise (inferiorly).
 - Placement around the marionette line to assist in delivering a seamless contour between chin and jawline.

The resultant effect was widening of the chin and straightening and defining the posterior jawline.

Phase two

During the second treatment, the patient was reassessed and a further 4ml of Ellansé M was added in the area of the zygoma and the right cheek. The facial contour in the right midface appeared flatter when viewed from above. Ellansé was placed superficially using a cannula from lateral access to contour the cheek and assist projection. Further placement superficially in the area of the angle of the mandible and chin was performed to add further anterior and width projection and really carve out the masculine look.

RESULTS

The patient was delighted with the results. His immediate response was, "I would date myself!" It's amazing how much confidence this kind of treatment gives the patient. As a clinician, the satisfaction of a happy patient and their immediate reaction is really what makes the job so special. After the initial session he was so pleased and shared compliments he got from friends and family. After the second treatment he was even more amazed. He really loves his chin cleft which nobody would know is artificially-made.

Post-treatment, the patient was reviewed at three weeks to allow the swelling to settle and to check for nodules. A final review is carried out after four months due to the development of collagen, in which time the treatment is expected to improve in appearance, soften and really come into its own. The patient can expect results to last up to 18 months, when he may require a top up (possibly sooner if he wants to further define his results – top ups will be dependent on patient wishes and expectations). As he is a young man and he lives healthily, his results are expected to last up to 24 months.

Patients treated with Ellansé can realistically expect to experience immediate definition, increased facial volumisation and improved appearance of folds, lines and wrinkles. It can also be used to treat the appearance of scars. Collagenesis continues for up to four months, as microspheres in the filler gel encourage the body to produce Type I collagen in response. 